



Clinically Suspected Myocarditis Temporally Related to COVID-19 Vaccination in Adolescents and Young Adults: Suspected Myocarditis After COVID-19 Vaccination

Dongngan T. Truong¹, MD, MS; Audrey Dionne¹, MD; Juan Carlos Muniz, MD; Kimberly E. McHugh, MD, MSCR; Michael A. Portman, MD; Linda M. Lambert, APRN; Deepika Thacker, MD; Matthew D. Elias¹, MD; Jennifer S. Li, MD; Olga H. Toro-Salazar, MD; Brett R. Anderson, MD, MBA, MS; Andrew M. Atz, MD; C. Monique Bohun¹, MB BCh; M. Jay Campbell¹, MD, MHA; Maryanne Chrisant, MD; Laura D'Addese¹, MD; Kirsten B. Dummer¹, MD; Daniel Forsha, MD; Lowell H. Frank, MD; Olivia H. Frosch¹, MD; Sarah K. Gelehrter, MD; Therese M. Giglia, MD; Camden Hebson, MD; Supriya S. Jain, MD; Pace Johnston, MD; Anita Krishnan¹, MD; Kristin C. Lombardi, MD; Brian W. McCrindle¹, MD, MPH; Elizabeth C. Mitchell¹, MD; Koichi Miyata¹, MD; Trent Mizzi, MD; Robert M. Parker, DO; Jyoti K. Patel, MD; Christina Ronai¹, MD, MEd; Arash A. Sabati¹, MD; Jenna Schauer, MD; S. Kristen Sexson Tejtzel, MD, PhD, MPH; J. Ryan Shea¹, MD; Lara S. Shekerdeman, MB ChB, MD, MHA; Shubhika Srivastava, MD, MBBS; Jodie K. Votava-Smith, MD; Sarah White, MD; Jane W. Newburger¹, MD, MPH

BACKGROUND: Understanding the clinical course and short-term outcomes of suspected myocarditis after the coronavirus disease 2019 (COVID-19) vaccination has important public health implications in the decision to vaccinate youth.

METHODS: We retrospectively collected data on patients <21 years old presenting before July 4, 2021, with suspected myocarditis within 30 days of COVID-19 vaccination. Lake Louise criteria were used for cardiac MRI findings. Myocarditis cases were classified as confirmed or probable on the basis of the Centers for Disease Control and Prevention definitions.

RESULTS: We report on 139 adolescents and young adults with 140 episodes of suspected myocarditis (49 confirmed, 91 probable) at 26 centers. Most patients were male (n=126, 90.6%) and White (n=92, 66.2%); 29 (20.9%) were Hispanic; and the median age was 15.8 years (range, 12.1–20.3; interquartile range [IQR], 14.5–17.0). Suspected myocarditis occurred in 136 patients (97.8%) after the mRNA vaccine, with 131 (94.2%) after the Pfizer-BioNTech vaccine; 128 (91.4%) occurred after the second dose. Symptoms started at a median of 2 days (range, 0–22; IQR, 1–3) after vaccination. The most common symptom was chest pain (99.3%). Patients were treated with nonsteroidal anti-inflammatory drugs (81.3%), intravenous immunoglobulin (21.6%), glucocorticoids (21.6%), colchicine (7.9%), or no anti-inflammatory therapies (8.6%). Twenty-six patients (18.7%) were in the intensive care unit, 2 were treated with inotropic/vasoactive support, and none required extracorporeal membrane oxygenation or died. Median hospital stay was 2 days (range, 0–10; IQR, 2–3). All patients had elevated troponin I (n=111, 8.12 ng/mL; IQR, 3.50–15.90) or T (n=28, 0.61 ng/mL; IQR, 0.25–1.30); 69.8% had abnormal ECGs and arrhythmias (7 with nonsustained ventricular tachycardia); and 18.7% had left ventricular ejection fraction <55% on echocardiogram. Of 97 patients who underwent cardiac MRI at a median 5 days (range, 0–88; IQR, 3–17) from symptom onset, 75 (77.3%) had abnormal findings: 74 (76.3%) had late gadolinium enhancement, 54 (55.7%) had myocardial edema, and 49 (50.5%) met Lake Louise criteria. Among 26 patients with left ventricular ejection fraction <55% on echocardiogram, all with follow-up had normalized function (n=25).

CONCLUSIONS: Most cases of suspected COVID-19 vaccine myocarditis occurring in persons <21 years have a mild clinical course with rapid resolution of symptoms. Abnormal findings on cardiac MRI were frequent. Future studies should evaluate risk factors, mechanisms, and long-term outcomes.

Key Words: adolescent ■ COVID-19 vaccines ■ myocarditis ■ young adult

Correspondence to: Dongngan T. Truong, MD, MS, 81 North Mario Capecchi Drive, Salt Lake City, UT 84113. Email dongngan.truong@hsc.utah.edu

Supplemental Material is available at <https://www.ahajournals.org/doi/suppl/10.1161/CIRCULATIONAHA.121.056583>.

Continuing medical education (CME) credit is available for this article. Go to <http://cme.ahajournals.org> to take the quiz.

For Sources of Funding and Disclosures, see page 355.

© 2021 American Heart Association, Inc.

Circulation is available at www.ahajournals.org/journal/circ

Clinical Perspective

What Is New?

- Suspected myocarditis temporally related to coronavirus disease 2019 (COVID-19) vaccination has been reported in adolescents ≥ 12 years old and young adults since the emergency use authorization of the Pfizer-BioNTech COVID-19 vaccine, in particular, in male adolescents and young adults.
- Although the majority of patients with suspected vaccine associated myocarditis have normal ventricular systolic function on echocardiogram, many have abnormal findings suggestive of myocarditis on cardiac MRI in the setting of elevated troponin and electrocardiographic changes.
- Ventricular arrhythmias and the need for inotropic/vasoactive medications were rare, and no patients died or required mechanical circulatory support.

What Are the Clinical Implications?

- Despite laboratory and cardiac MRI evidence of myocardial injury, the majority of adolescents and young adults with suspected myocarditis after COVID-19 vaccination have rapid recovery of symptoms and mild clinical course.
- Further studies are needed to better understand the timing of the resolution of myocardial injury, mechanism of myocardial injury, and long-term outcomes.

Nonstandard Abbreviations and Acronyms

cMRI	cardiac MRI
ICU	intensive care unit
IVIG	intravenous immunoglobulin
LVEF	left ventricular ejection fraction
MIS-C	multisystem inflammatory syndrome in children associated with COVID-19
NSAID	nonsteroidal anti-inflammatory drug
VAM	vaccine-associated myocarditis

Rare cases of myocarditis have been reported in adults¹⁻³ after the coronavirus disease 2019 (COVID-19) vaccination in Israel⁴ and in the US military,⁵ with most cases occurring in men < 30 years old. Since the authorization to administer the Pfizer-BioNTech COVID-19 vaccine in those as young as 12 years of age, suspected myocarditis temporally related to the vaccine has also been reported in adolescents.⁶⁻⁸ Myocarditis has been associated with other vaccines, such as smallpox⁹ and influenza,¹⁰ although data are limited regarding symptoms, clinical course, and short-term outcomes of suspected myocarditis after COVID-19 vaccination. On June 23, 2021, the Centers for Disease Control and Prevention (CDC) Advisory Committee on

Immunization Practices reported a likely link between mRNA COVID-19 vaccination and myocarditis, in particular, in those ≤ 39 years old.¹¹ We aim to describe a large case series of suspected myocarditis temporally related to the COVID-19 vaccine in adolescents and young adults < 21 years old across the United States and Canada.

METHODS

The data that support the findings of this study are available from the corresponding author on reasonable request.

Patients

We collected data retrospectively for adolescents and young adults < 21 years old who presented with symptoms, laboratory markers, and imaging findings concerning for myocarditis within 30 days of COVID-19 vaccination from 26 pediatric medical centers across the United States and Canada before July 4, 2021. We included patients with clinically suspected myocarditis^{12,13} who had elevated troponin levels and abnormal ECGs, cardiac function on noninvasive imaging, or findings consistent with myocarditis on cardiac MRI (cMRI), including myocardial edema or late gadolinium enhancement.¹⁴ Cases of suspected vaccine-associated myocarditis (VAM) were categorized as probable or confirmed using the CDC case definitions (Table 1).¹¹

We excluded patients in whom troponin levels were not measured or who had normal troponin levels or who had a plausible alternative cause for suspected myocarditis. Evaluations for alternative causes were at the discretion of sites on the basis of local assessments (Table S1). If a patient presented with symptoms and findings suggestive of myocarditis after > 1 vaccine dose, the more severe presentation was added to the aggregate data for analysis. The study was approved by the institutional review boards of each center, and waivers of consent were granted.

Data Obtained

We collected deidentified and targeted demographic, clinical, laboratory, imaging and ECG, and short-term outcomes data. Previous COVID-19 infection was defined as having a personal history of laboratory-confirmed severe acute respiratory syndrome coronavirus 2 (SARS CoV-2) testing and having had symptoms and immediate household family members who tested positive for SARS CoV-2, but the patient was not tested. Left ventricular systolic function was categorized as normal if graded as normal by local assessment, or if left ventricular ejection fraction (LVEF) was $\geq 55\%$; mildly decreased systolic function was defined as LVEF $< 45\%$ to 54% , moderately decreased if 35% to 44% , and severely decreased if $< 35\%$. The decision and timing to obtain cMRIs were at the discretion of the local clinical teams, and cMRIs were performed using local protocols (Table S2). Data on cMRIs were collected retrospectively from clinical reports.

Statistical Analyses

Descriptive statistics include percentages for discrete variables and median values with range or interquartile range for

Table 1. Centers for Disease Control and Prevention Case Definitions for Probable and Confirmed Cases of COVID-19 Vaccine-Associated Myocarditis

Probable case	Confirmed case
≥1 new or worsening symptom	≥1 new or worsening symptom:
Chest pain, pressure, or discomfort	Chest pain, pressure, or discomfort
Dyspnea or shortness of breath	Dyspnea or shortness of breath
Palpitations	Palpitations
Syncope	Syncope
AND ≥1 new finding of:	AND
Elevated troponin	Histological confirmation of myocarditis
Abnormal ECG or rhythm monitoring consistent with myocarditis	OR
Abnormal ventricular systolic function or wall motion abnormality on echocardiogram	Elevated troponin AND cardiac MRI findings consistent with the original or revised Lake Louise criteria for myocarditis ¹⁴
Cardiac MRI findings consistent with the original or revised Lake Louise criteria for myocarditis ¹⁴	AND no other identifiable cause of the symptoms and findings
AND no other identifiable cause of the symptoms and findings	

Adapted from Gargano et al¹¹ with permission. Copyright © 2021, Centers for Disease Control and Prevention. COVID-19 indicates coronavirus disease 2019.

continuous variables. A Fisher exact test or a Wilcoxon rank-sum test was used to compare markers of illness severity in patients who did versus did not undergo cMRI, and time to cMRI in those that were normal versus abnormal. Markers of illness severity included the need for an intensive care unit (ICU) stay, left ventricular dysfunction on echocardiogram, and troponin I levels, which were performed more frequently than troponin T. All analyses were performed using Stata 11.2 (College Station, TX).

RESULTS

As of July 4, 2021, 146 episodes of clinically suspected VAM occurred in 145 adolescents and young adults <21 years old at 26 centers, with 6 patients excluded because of the lack of abnormal troponin. Thus, 140 episodes in 139 patients were analyzed. One patient presented with suspected myocarditis after both doses of the Pfizer-BioNTech vaccine, with a more severe course after the second dose; data from his second episode are included in the aggregate analysis, as detailed later in this article. The majority of patients were White (n=92, 66.2%), non-Hispanic (n=96, 69.1%), and male (n=126, 90.6%) with a median age of 15.8 years (range, 12.1–20.3; IQR, 14.5–17.0; Table 2). On the basis of symptoms, laboratory, and imaging data, 49 (35.0%) episodes of suspected myocarditis met criteria for confirmed myocarditis by CDC classification, and the remaining 91 (65.0%) episodes would be classified as probable. No patients underwent endomyocardial biopsy.

Of the 140 episodes of clinically suspected VAM, 124 (88.6%) were evaluated with SARS CoV-2 polymerase chain reaction testing at the time of presentation (Table S1), all of which were negative. Two patients had positive polymerase chain reaction testing within 32 days of presentation of suspected myocarditis, and thus were

not tested again. Fifteen (10.7%) patients had evidence of previous COVID-19 infection by history (n=5), positive nucleocapsid antibodies (n=5), or both (n=5). Previous COVID-19 infection occurred <1 month to up to 10 months before the suspected myocarditis episode in the 10 patients with a known history. The majority (n=94, 67.6%) had no history of previous infection and had negative nucleocapsid antibodies to COVID-19, although in 30 patients (21.6%) the history was unknown and no nucleocapsid antibody testing was performed (Table 2). Of the 12 patients who presented with myocarditis after the first dose of vaccine, 6 had a history of previous COVID-19 infection or had the presence of nucleocapsid antibodies. Evaluation for alternative microbial causes for suspected myocarditis varied (Table S1), with no plausible alternatives determined by centers. None had a previous history of multisystem inflammatory syndrome in children associated with COVID-19 (MIS-C).

Vaccination Data, Symptoms, and Clinical Course

Most patients with suspected myocarditis received mRNA vaccine, with 131 (94.2%) after the Pfizer-BioNTech and 5 (3.6%) after the Moderna vaccines. One case (0.7%) occurred after the Johnson & Johnson vaccine. The brand of vaccine was unknown in 2 patients. Patients presented more frequently after the second dose (n=128, 91.4%; Table 3). Onset of symptoms occurred at a median of 2 days (range, 0–22; IQR, 1–3) after vaccine administration, with 5 patients presenting with symptoms 7 to 20 days and only 1 presenting with symptoms ≥21 days after vaccination. Chest pain was the most common symptom, occurring in 138 patients (99.3%). Fever and shortness of breath each occurred in 30.9% and 27.3% of patients, respectively (Table 3).

Table 2. Demographic Variables and History of COVID-19 Infection

Variable	Value
Total adolescents and young adults, n	139
Age, y (range; interquartile range)	15.8 (12.1–20.3; 14.5–17.0)
12 to <16, n (%)	73 (52.5)
16 to ≤20, n (%)	66 (47.5)
Male sex, n (%)	126 (90.6)
Race, n (%)	
White	92 (66.2)
Black	6 (4.3)
Asian	9 (6.5)
Native American or Alaskan Native	2 (1.4)
Other	13 (9.4)
Unknown or refused to answer	17 (12.2)
Ethnicity, n (%)	
Hispanic	29 (20.9)
Unknown/refused to answer	14 (10.1)
Previous COVID-19 infection	
Yes (by history), n (%)	10 (7.2)
Months from known COVID-19 infection, n (range)	5 (<1–10)
Yes (by COVID-19 nucleocapsid antibody; n=82), n (%)	10 (7.2)
No history and negative nucleocapsid antibody, n (%)	94 (67.6)
Unknown history and no nucleocapsid antibody tested, n (%)	30 (21.6)

COVID-19 indicates coronavirus disease 2019.

Although 26 patients (18.7%) were managed in ICUs, inotropic/vasoactive support was used in only 2 (1.4%): 1 patient was treated with epinephrine and norepinephrine, and the other patient was treated with milrinone. No patient required extracorporeal membrane oxygenation. All patients survived. The median hospital length of stay was 2 days (range, 0–10; IQR, 2–3).

Most patients (n=113, 81.3%) were treated with non-steroidal anti-inflammatory drugs (NSAIDs); 76 (54.7%) were treated with NSAIDs alone. Intravenous immunoglobulin (IVIG) was administered to 30 (21.6%) patients, with glucocorticoids also given to 30 patients (Figure 1). Glucocorticoid regimens varied, ranging from intravenous glucocorticoids alone (n=6) at doses of 0.5 to 10 mg·kg⁻¹·d⁻¹ for 1 to 3 days, to oral glucocorticoids alone (n=2) at 0.5 to 0.67 mg·kg⁻¹·d⁻¹ for 5 to 10 days, or intravenous and oral glucocorticoids (n=22) with a taper over 2 to 73 days. Colchicine was used in 11 patients (7.9%). Twelve patients (8.6%) had complete clinical improvement without any anti-inflammatory therapies.

Laboratory Data

All patients had elevated troponin I (median, 8.12 ng/mL; IQR, 3.50–15.90 ng/mL; n=111) or T (median, 0.61

Table 3. COVID-19 Vaccine and Clinical Data

Variable	Value
Total adolescents and young adults, n	139
Brand of COVID-19 vaccine, n (%)	
Pfizer-BioNTech	131 (94.2)
Moderna	5 (3.6)
Johnson & Johnson	1 (0.7)
Unknown	2 (1.4)
Dose of vaccine with symptoms (n=140), n (%)	
First dose	12 (8.6)
Second dose	128 (91.4)
Days from vaccine administration to symptom onset, n (range; interquartile range)	2 (0–22; 1–3)
Symptoms, n (%)	
Chest pain	138 (99.3)
Fever (temperature ≥100.4 °F or tactile)	43 (30.9)
Shortness of breath	38 (27.3)
Headache	22 (15.8)
Myalgias	19 (13.7)
Vomiting	17 (12.2)
Fatigue	11 (7.9)
Palpitations	7 (5.0)
Rash	5 (3.6)
Diarrhea	3 (2.2)
Conjunctivitis	1 (0.7)
Intensive care unit stay, n (%)	26 (18.7)
Inotropes used, n (%)	2 (1.4)
Days in hospital, n (range, interquartile range)	2 (0–10; 2–3)
Mortality, n	0

COVID-19 indicates coronavirus disease 2019.

ng/mL; IQR, 0.25–1.3 ng/mL; n=28; Table 4). Median C-reactive protein levels were mildly elevated (3.3 mg/dL; IQR, 1.1–6.2 mg/dL; n=116). The median brain natriuretic peptide level was within the normal range (55.0 pg/mL; IQR, 18.9–147.0 pg/mL; n=101) and median NT-proBNP (N-terminal pro-B-type natriuretic peptide) was mildly elevated (159 pg/mL; IQR, 91.5–810.3 pg/mL; n=8; Table 4).

ECGs and Arrhythmias

ECGs were obtained in 138 patients (99.3%); 97 (69.8%) of the ECGs showed abnormal results. The most common abnormal ECG findings were ST-segment and T-wave abnormalities/elevation (n=95, 97.9%; Figure 2A), with low voltages also seen in some (n=5, 3.6%). Of the 5 patients with low voltages, 3 had normal voltages within 3.5 weeks; one did not follow up with the contributing site, and thus no follow-up ECGs were available; one continued to have low voltages at 5.5 weeks. Occasional premature ventricular (n=3) or atrial (n=1)

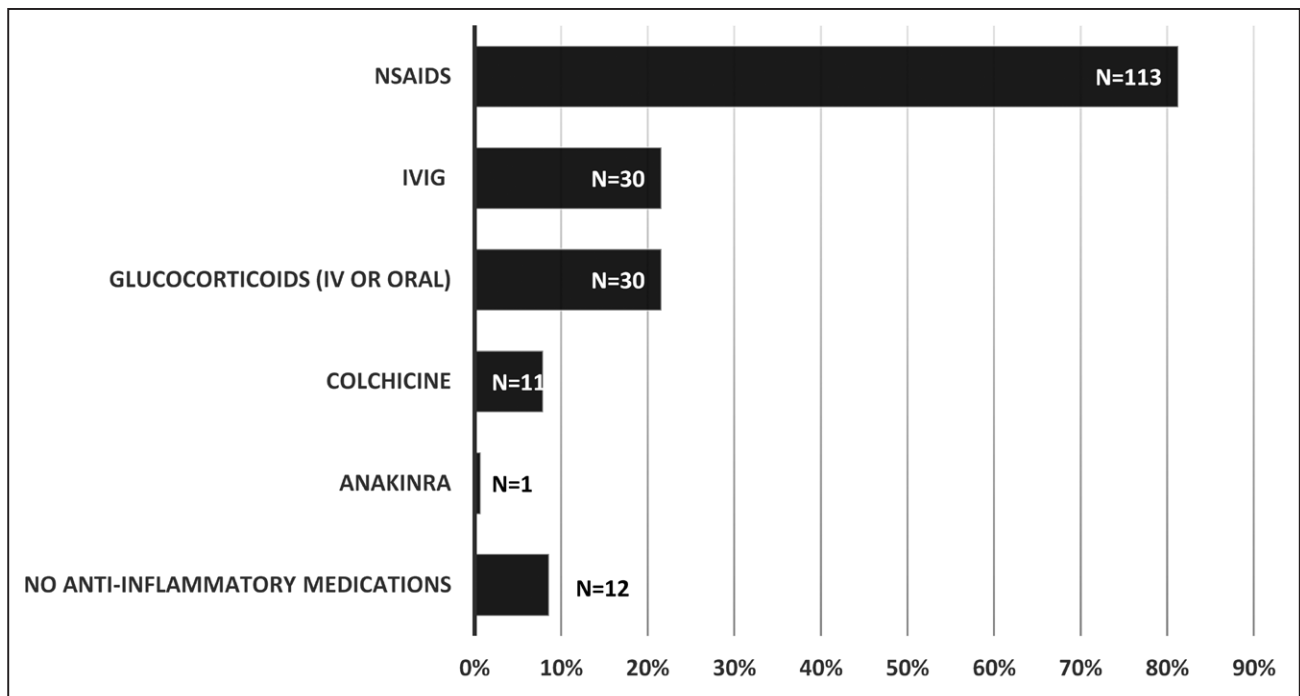


Figure 1. Anti-inflammatory therapies used in the treatment of suspected myocarditis temporally related to the COVID-19 vaccination.

COVID-19 indicates coronavirus disease 2019.

contractions, atrial tachycardia (n=1), first-degree atrioventricular block (n=1), and complete heart block (n=1) were observed, although uncommon.

Nonsustained ventricular tachycardia occurred in 7 patients (5.0%), either on ECG, telemetry, or ambulatory monitoring. Six had normal LVEF on echocardiogram, and one had mildly decreased systolic function (LVEF=50%). Of the 6 patients with ventricular tachycardia who underwent cMRI, all had late gadolinium enhancement and myocardial edema. Two patients were treated with NSAIDs alone, 1 with IVIG and NSAIDs, 2 with IVIG and glucocorticoids, 1 with glucocorticoids and NSAIDs, and 1 with IVIG, glucocorticoids, and NSAIDs; this last patient had a 15-beat run of nonsustained ventricular tachycardia on a Holter monitor (Figure 2B) and was readmitted and treated with atenolol.

One patient presented to an emergency department with chest pain and was diagnosed with complete heart block. He was admitted to the pediatric ICU for monitoring, and no pacing was needed. Ventricular systolic function was normal on echocardiogram, and cMRI revealed late gadolinium enhancement without evidence of myocardial edema. This patient was treated with IVIG and steroids, and his rhythm recovered within 24 hours of admission.

Cardiac Imaging

Echocardiography was performed in all patients. The majority (n=113, 81.3%) had normal systolic function, whereas 22 (15.8%) had mild, 2 (1.4%) had moderate,

and 2 (1.4%) had severe dysfunction (Table 4). Twenty-five patients with LVEF<55% had recovery of systolic function to normal, with 1 patient awaiting outpatient follow-up at the time of this submission. Only 1 patient had a pericardial effusion, which was small. One patient had coronary artery dilation, with further details as noted later on in this article.

Initial cMRI was performed in 97 patients at a median of 5 days (range, 1–88; IQR, 3–17) after symptom onset, of whom 75 (77.3%) had abnormalities. Among patients with abnormal cMRIs, late gadolinium enhancement was noted in 74 (98.7%) and myocardial edema was present in 54 (72.0%; Table 4, Figure 3). Among the 97 cMRIs performed, 76.3% and 55.7% had evidence of late gadolinium enhancement or myocardial edema, respectively, and 49 (50.5%) met Lake Louise criteria for myocarditis (Table 4, Table S2). Of those with abnormal cMRIs, 62 (82.7%) occurred in patients with normal left ventricular systolic function on echocardiogram. Patients with versus without a cMRI did not differ significantly with respect to ICU admission (24.1% versus 16.7%, $P=0.26$), having \geq mild left ventricular systolic dysfunction (23.2% versus 11.9%, $P=0.17$), or troponin I levels (9.18 versus 5.03 ng/mL, $P=0.08$). Median days from symptom onset to cMRI were significantly shorter for patients with abnormal versus normal cMRIs (4 versus 24 days, $P<0.01$). However, 6 of the 15 cMRIs performed >30 days after symptom onset had findings at late gadolinium enhancement (even at up to 88 days), whereas 7 of the 22 normal cMRIs were obtained within 7 days of symptom onset.

Table 4. Laboratory, ECG, and Imaging Data

Variable	Value
Peak laboratory values	
Troponin (N=139)	
Troponin I, ng/mL (n=111) (Reference normal <0.04 ng/mL)	8.12 (IQR, 3.50–15.90)
Troponin T, ng/mL (n=28) (Reference normal ≤0.014 ng/mL)	0.61 (IQR, 0.25–1.30)
Brain natriuretic peptide, pg/mL (n=101) (Reference normal <100 pg/mL)	55.0 (IQR, 18.9–147.0)
NT-Pro-BNP, pg/mL (n=8) (Reference normal <125 pg/mL)	159 (IQR, 91.5–810.3)
C-Reactive protein, mg/dL (n=116) (Reference normal <0.3 mg/dL)	3.3 (IQR, 1.1–6.2)
Testing/imaging	
ECG (N=138), n (%)	
Abnormal	97 (69.8)
Normal	41 (29.5)
Abnormal ECG findings or arrhythmias (n=97)	
ST- or T-wave changes/elevation	95 (97.9)
Nonsustained ventricular tachycardia (ECG, telemetry, or ambulatory monitoring)	7 (5.0)
Low-voltage QRS	5 (3.6)
Premature ventricular contractions (ECG, telemetry, or ambulatory monitoring)	3 (2.2)
Atrial tachycardia (ECG, telemetry, or ambulatory monitoring)	1 (0.7)
Premature atrial contractions	1 (0.7)
First-degree atrioventricular block	1 (0.7)
Complete heart block	1 (0.7)
Echocardiogram (N=139)	
Left ventricular ejection fraction, n (%)	
Normal (≥55%)	113 (81.3)
Mild dysfunction (45%–54%)	22 (15.8)
Moderate dysfunction (35%–44%)	2 (1.4)
Severe dysfunction (<35%)	2 (1.4)
Pericardial effusion ≥small in size, n (%)	1 (0.7)
Cardiac MRI (n=97)	
Days from symptom onset to cardiac MRI	5 (range 1–88; IQR, 3–17)
Left ventricular ejection fraction	60.0% (55.0%–62.7%)
Right ventricular ejection fraction	57.3% (52.9%–62.0%)
Abnormal findings, n (%)	75 (77.3)
Late gadolinium enhancement	74 (98.7)
Myocardial edema	54 (72.0)
Lake Louise criteria (yes), n (%)	49 (50.5)
Centers for Disease Control and Prevention case definition of myocarditis (N=140), n (%)	
Confirmed	49 (35.0)
Probable	91 (65.0)

IQR indicates interquartile range; and NT-proBNP, N-terminal pro-B-type natriuretic peptide.

Cases of Interest

Patient With Suspected Myocarditis After the First and Second Vaccine Doses

A 17-year-old White male patient with a history of obesity and hyperlipidemia and no known previous history of COVID-19 infection had presumed myocarditis after both the first and second doses of the Pfizer-BioNTech vaccine. He had onset of chest pain 20 days after his first dose and presented to the emergency department; laboratory tests showed a peak troponin I of 0.45 ng/mL. No testing for acute or previous COVID-19 infection was performed, and no other causes for myocarditis were evaluated at that time. His ECG and echocardiogram were normal, and cMRI was not performed. He was treated with NSAIDs as an outpatient. His chest pain resolved, with a decrease in troponin level to 0.3 ng/mL 3 days after presentation.

He received a second dose of vaccine 10 days after presenting with his initial episode of suspected myocarditis after vaccination (ie, 30 days after receiving his first dose of vaccine). Chest pain occurred 5 days after his second vaccine dose, with a much higher peak troponin I level of 34.5 ng/mL. His ECG showed diffuse ST-segment changes and nonsustained ventricular tachycardia. Left ventricular systolic function was normal. cMRI showed late gadolinium enhancement and myocardial edema. He was treated with IVIG and NSAIDs. Nucleocapsid IgG testing sent before IVIG was negative. Thyroid peroxidase antibody group and Sjogren syndrome-A antibodies were positive, but these were obtained after IVIG administration, and he had no previous history of symptoms or findings suggestive of these disorders. He was hospitalized for 4 days, which included ICU admission, although no inotropic or vasoactive support was required.

Of note, he also had a history of suspected myocarditis at age 10 years, with symptoms of fever, sore throat, and chest pain. At that time, he was admitted to the ICU, with troponin I level of 0.78 ng/mL, normal ECG, and normal function by echocardiography. No cMRI was performed associated with this episode.

Patient With Suspected Myocarditis and Coronary Artery Dilation

A 16-year-old Black male patient who had a COVID-19 infection 32 days before receiving his first dose of Pfizer-BioNTech vaccine had dilated coronary arteries on presentation with suspected VAM. He presented with chest pain 7 days after the first dose of vaccine; he had no fevers or other organ system involvement, and he did not meet CDC criteria for MIS-C¹⁵ or American Heart Association criteria for complete or incomplete Kawasaki disease.¹⁶ Peak C-reactive protein was 0.62 mg/dL and peak troponin I level was 17.5 ng/mL. Nucleocapsid antibody and spike antibody testing were positive. His ECG showed ST-segment elevation. Telemetry showed

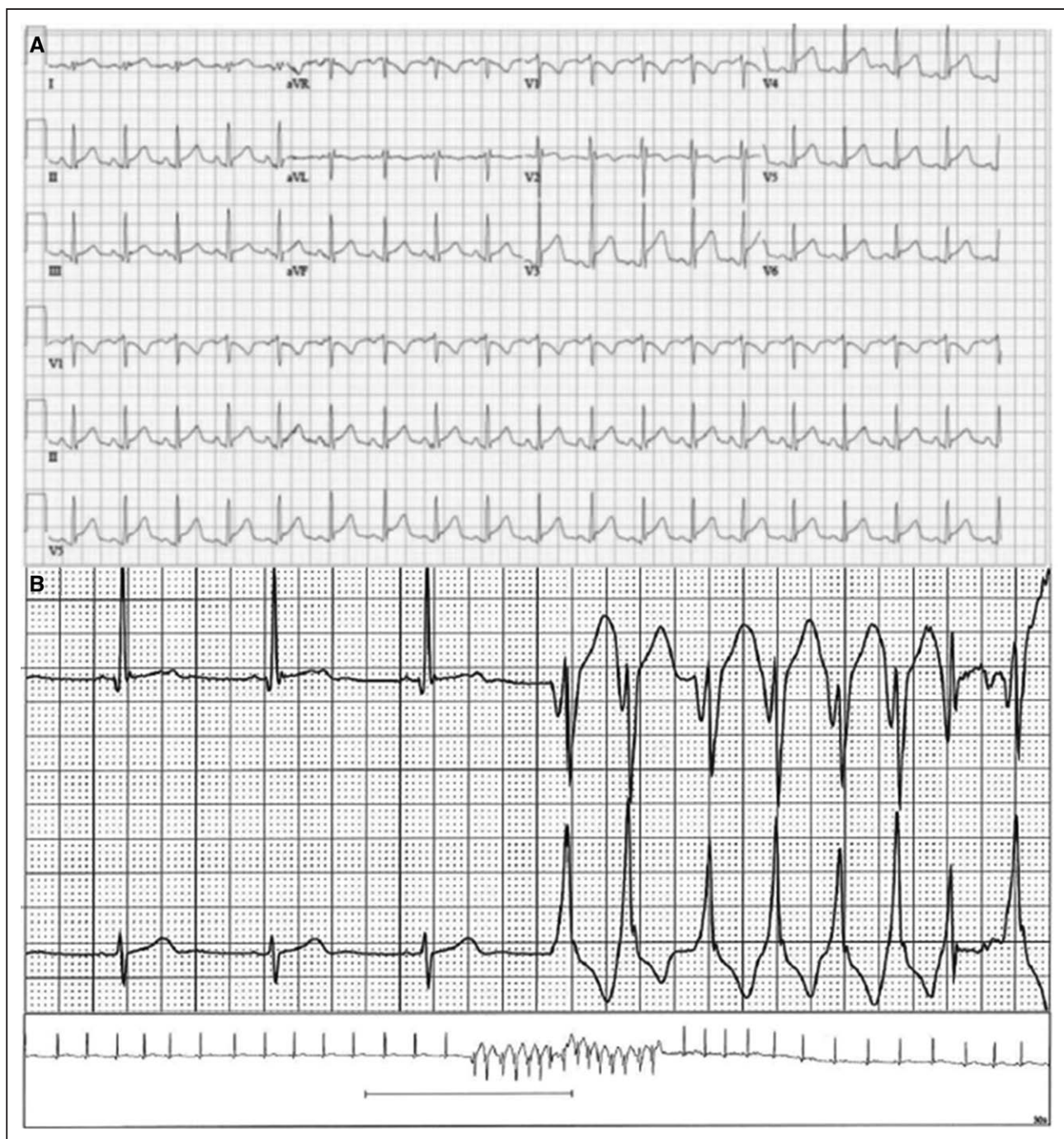


Figure 2. Electrocardiographic abnormalities and rhythm disturbances seen in suspected myocarditis temporally related to vaccination.

A, Diffuse ST elevation on the ECG of a 15-year-old boy presenting with chest pain and elevated troponin levels 2 days after his second Pfizer vaccine dose. **B**, Holter monitor tracing showing a 15-beat run of nonsustained ventricular tachycardia at a rate of ≈ 170 beats per minute in a 17-year-old boy who had ventricular couplets and a 3-beat run of nonsustained ventricular tachycardia during hospitalization for suspected myocarditis after his second Pfizer-BioNTech vaccine dose.

ventricular ectopy for which he was started on metoprolol. He had no ventricular tachycardia or other sustained arrhythmias while in the hospital, but routine outpatient screening with a Holter monitor showed atrial ectopic tachycardia with rare atrial and ventricular ectopy ($<1\%$). His echocardiogram at presentation showed an LVEF

of 51% with a small aneurysm of the right coronary artery (Z-score of 3.8) and mild dilation of the left anterior descending coronary artery (Z-score of 2.2) (Boston Z-score system). The left main coronary artery Z-score was normal. He was treated with glucocorticoids and aspirin. On hospital day 3, the right coronary artery Z-score had

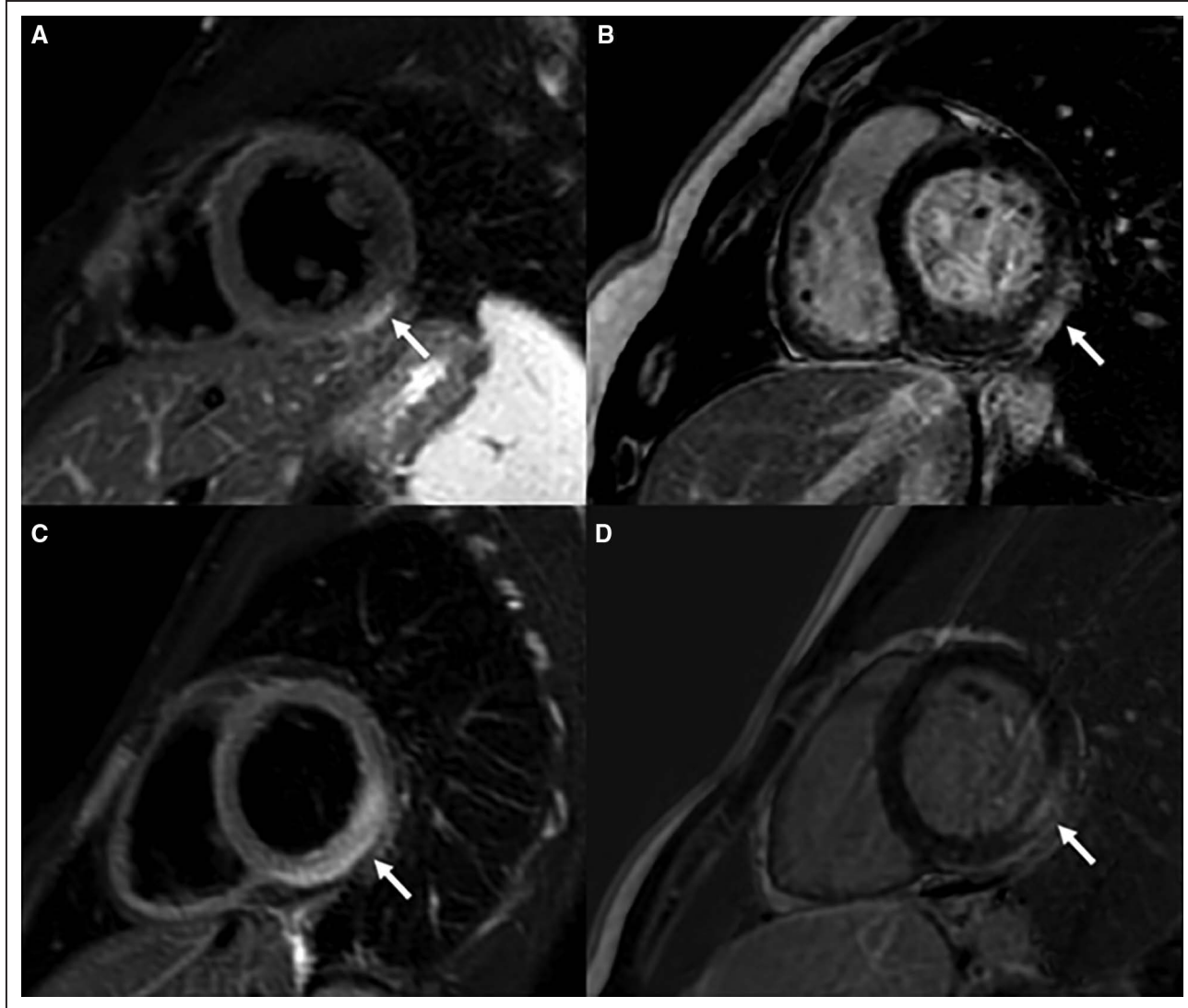


Figure 3. Cardiac magnetic resonance images from a 16-year-old boy (A and C) obtained 5 days after second dose (2 days after symptom onset) and a 15-year-old boy (B and D) 4 days after second dose (2 days after symptom onset).

T2 weighted images (A and C) show focal inferolateral wall edema. Late gadolinium enhancement images (B and D) show subepicardial and midwall enhancement characteristic of myocarditis.

decreased to 2.6 and the left coronary artery dimensions and LVEF had normalized. One month later, the right coronary artery Z-score was 2.9, and it remained enlarged at his most recent evaluation 76 days after presentation. He has not yet received his second dose of vaccine.

DISCUSSION

In this large case series from North America, we describe 139 adolescents and young adults <21 years old who had 140 episodes of clinically suspected myocarditis temporally related to COVID-19 vaccination. The CDC case definition¹¹ of confirmed myocarditis after vaccination was met in 35%, with elevated troponin levels and cMRIs that met Lake Louise criteria for myocarditis, and the remainder met criteria for probable cases. Symptoms and clinical findings typically developed within a

week of vaccination and occurred in most patients after the second dose. Ventricular tachycardia and complete heart block were uncommon complications (5.8%) and occurred in the absence of ventricular systolic dysfunction in all but one in this series. Many patients (80.6%) had pseudoinfarct presentation with chest pain, ST changes on ECG, and elevated troponin with normal left ventricular systolic function.¹⁷ In the <20% of patients with depressed LVEF on echocardiogram at presentation, systolic function normalized in all who had follow-up echocardiograms at the time of this submission. Although only 50.5% of cMRIs performed met Lake Louise criteria for myocarditis, findings of late gadolinium enhancement were seen in 76.3% and myocardial edema in 55.7% of all cMRIs performed. More than 80% of these abnormal cMRIs occurred in the setting of normal systolic function on echocardiogram. No patients died or required

extracorporeal membrane oxygenation support, and nearly 1 in 5 patients were admitted to an ICU, although the use of inotropic/vasoactive support was rare. Similar to patients who have myocarditis with a pseudoinfarct presentation,^{12,17,18} most patients had a relatively benign clinical course. Longer-term surveillance is needed, however, to determine the natural history of suspected myocarditis temporally related to COVID-19 vaccines.

The findings in our large case series of adolescents and young adults with clinically suspected myocarditis after COVID-19 vaccination add to previously reported, smaller case series and case reports.^{6–8,19–21} Our large series is similar to earlier reports in finding a predominance of White and non-Hispanic men, with symptoms typically within a week of the second dose of mRNA vaccine and cMRI abnormalities seen frequently.²¹ A unique feature of our series is a patient with episodes of myocarditis after both his first and second doses of the Pfizer-BioNTech vaccine, although there are other features of this patient's clinical history that may make his case less generalizable. Nonetheless, the greater severity of symptoms and laboratory findings in this patient after his second versus first dose supports the consideration of withholding or deferring a second dose of mRNA COVID-19 vaccine in patients with suspected myocarditis after the first dose until more information is available.²²

We also describe a patient with coronary artery involvement that, to our knowledge, has not been previously reported in patients with post-COVID-19 vaccine myocarditis. However, coronary artery dilation has been described in non-COVID-19 viral myocarditis²³ and in myocarditis in the setting of COVID-19 infection.²⁴ Because this patient had COVID-19 infection 32 days before his vaccination, it is unclear if the coronary artery findings are related to the infection, the vaccination, a combination of the 2, or completely unrelated. Although the timing of his presentation and cardiac findings are similar to those that have been described in MIS-C, he otherwise did not meet CDC criteria for MIS-C. Coronary artery Z-scores, that is, coronary artery dimensions normalized for body surface area, have high inter- and intraobserver agreement in young children.²⁵ However, poor windows may limit the technical feasibility of coronary measurements in larger children and adolescents. Until more data are available, focused echocardiographic coronary artery imaging in patients presenting with suspected myocarditis after COVID-19 vaccination may be warranted to determine the frequency and evolution of this finding.

Risk factors and mechanisms for the development of suspected myocarditis after COVID-19 vaccination are unknown. White, non-Hispanic Americans comprised nearly 60% of those who had at least 1 vaccine dose in the United States before to July 4, 2021.²⁶ Thus, race and ethnic distributions observed in our study likely

reflect differences in vaccination rates rather than susceptibility. Males outnumber females in nonvaccine forms of myocarditis in both childhood²⁷ and adulthood,^{28,29} in particular, with pseudoinfarct presentation, with the highest incidence in adolescent and young adult males.²⁹ Although 66% to 77% of non-COVID-19 myocarditis occurs in males,^{27,29} the male predominance in suspected VAM is strikingly higher, with males constituting 90.6% of cases in our series and all cases in smaller earlier reports.^{6–8,19} The underlying genetic differences or immune response mechanisms that underly the profound susceptibility of young males in VAM are uncertain. Mechanisms of myocardial dysfunction posited in MIS-C, such as hyperinflammatory state and cytokine storm,³⁰ autoantibodies,^{31,32} or molecular mimicry,³³ may play a role. Other potential mechanisms including reaction to adjuvant, nanoparticles, or other components of the vaccine³⁴ could also be important mechanistically. Negron et al³⁵ have suggested an abundance of the SARS-CoV-2 Spike protein S1 subunit, produced as a result of mRNA vaccines, could interact with toll-like receptor 4, activate NF- κ B (nuclear factor- κ B), thereby eliciting cardiac inflammation and myocyte toxicity. Further studies are critically needed to elucidate risk factors and underlying mechanisms for the development of potential VAM.

Optimal treatment strategies for clinically suspected VAM are unknown, with treatments ranging in our series from no anti-inflammatory therapies to glucocorticoids with or without IVIG, and even anakinra in 1 case. Glucocorticoids have not been shown to be beneficial, and may be harmful, in viral myocarditis. However, they have been used in virus-negative myocarditis.^{12,13,36,37} Clinicians may have administered immunomodulatory agents to some patients in this series because VAM results from an immune-mediated response, rather than direct viral infection of the myocardium.³⁴ The use of IVIG and glucocorticoids in \approx 20% of patients in this series may also reflect extrapolation from care strategies of MIS-C and non-COVID-19 myocarditis. Glucocorticoids and IVIG, alone or in combination, are used commonly in MIS-C,³⁸ with studies suggesting recovery of cardiac function³⁹ and decreased risk of development of left ventricular dysfunction and shorter ICU stays⁴⁰ when used in combination. Despite equivocal data^{41,42} and some recommendations against its use in non-COVID-19 myocarditis,^{13,42} NSAIDs were the most commonly used medication in our series. However, we could not discern whether NSAIDs were prescribed for pain management, for anti-inflammatory effects, or for both. Likewise, although colchicine is used in the treatment of pericardial disease,⁴³ it is not indicated for the treatment of myocarditis. Its use in nearly 8% of patients in this series may reflect concerns for pericardial involvement, that is, myopericarditis. Last, we did not have sufficient sample size to analyze the efficacy of different medical regimens with propensity score matching.

Although VAM, even if mild in the majority, is a cause of great concern, its risk must be balanced against critical illness and cardiovascular involvement associated with acute or postacute sequelae of COVID-19 infection,⁴⁴ and particularly with MIS-C in youth.⁴⁴⁻⁴⁶ In large studies of patients with MIS-C, 73.8% have been admitted to the ICU,⁴⁴ 30% to 62% have required inotropic/vasoactive support,⁴⁴⁻⁴⁶ 3.3% were on extracorporeal membrane oxygenation, and 1.9% died.⁴⁴ Children and adolescents with acute COVID-19 can also be quite ill; Feldstein et al⁴⁴ reported that 43.8% of hospitalized patients <21 years old with acute COVID-19 were admitted to an ICU, of whom 8.7% were on vasoactive support, 1.4% were on extracorporeal membrane oxygenation, and 1.4% died. Cardiovascular injury or involvement is common in MIS-C, with decreased LVEF in 34.2% to 52.0%⁴⁴⁻⁴⁶ and coronary artery aneurysms in 13.4%.⁴⁴ In contrast to MIS-C and hospitalized pediatric patients with COVID-19, the frequencies of ICU admission and of inotropic/vasoactive support were only 18.7% and 1.4%, respectively, in our suspected VAM series. Frequency of left ventricular systolic dysfunction was lower (18.7%) than that reported in MIS-C. Some studies have suggested that diastolic dysfunction parameters persist, despite normalization of systolic function in COVID-19 suspected myocarditis.^{47,48} However, diastolic function and strain parameters were not assessed in our case series, so direct comparisons could not be performed.

The definition of myocarditis varies somewhat in the literature. Endomyocardial biopsy is the current reference standard to confirm the diagnosis of myocarditis,^{12,13,49} but it is used infrequently in pediatrics⁴⁹ and adults.¹² Furthermore, a high false-negative rate has been reported in myocarditis, because biopsy samples are taken randomly and myocarditis tends to be focal.⁴⁹ In the 2021 American Heart Association Diagnosis and Management of Myocarditis in Children Statement, a paradigm shift in the diagnosis of myocarditis is described, with greater reliance on tissue characterization through cMRI.⁴⁹ None of the patients in our series underwent myocardial biopsy to confirm the diagnosis of myocarditis, likely reflecting clinical practice and an unfavorable risk/benefit ratio in children and young adults who recovered quickly after presentation with suspected myocarditis.

Although this case series cannot determine causality of suspected myocarditis from COVID-19 vaccination, the number of cases of suspected myocarditis within a short time frame after COVID-19 vaccination would be unlikely to be secondary to chance alone. The CDC has determined that the observed frequency of reporting of suspected myocarditis/pericarditis temporally related to COVID-19 vaccination is higher than the expected background rate of myocarditis/pericarditis.⁵⁰

Our study design did not allow us to estimate the incidence or risk of myocarditis in adolescents and young adults after COVID-19 vaccine or to compare these risks

with those from severe cardiac effects in youth after acute COVID-19 or MIS-C within each center's catchment area. Of note, the CDC has estimated reporting rates of 62.75 (0.006%) and 50.2 (0.005%) myocarditis cases per 1 million mRNA COVID-19 vaccine doses administered in the 12- to 17-year and 18- to 24-year age groups, respectively.²² Using data from Washington state, Schauer et al²⁰ estimated an incidence of 0.008% in adolescents aged 16 to 17 years and 0.01% in those aged 12 to 15 years. The benefit-risk analysis presented by the CDC has suggested a positive balance for all age groups of both sexes, although the balance varies by age and sex; assessments of benefit-risk for each individual are also necessary.^{11,22}

Other limitations to this study relate to its retrospective and descriptive nature. The evaluation for alternative causes and management strategies for suspected myocarditis, such as indications for ICU admission, was decided by local clinicians rather than by study protocol. Furthermore, no patients underwent endomyocardial biopsy to rule out direct viral infection of the myocardium. Therefore, some patients included in this series may have an alternative diagnosis, although the high numbers of clinically suspected myocarditis presenting within a week of vaccination in a 3-month period would be unusual. Also, approaches to image acquisition of cMRIs were not standardized and relied on local protocols. Likewise, echocardiograms and cMRIs were not interpreted in core laboratories, and we did not assess diastolic function parameters. Because cMRIs were obtained in only 69.3% of cases in our series at the time of submission, we may be over- or underestimating the frequency of abnormal cMRI findings. There may also be selection bias in who underwent cMRIs, although, in our analysis, there was no statistical difference in troponin levels, frequency of LVEF<55%, or ICU stays between those who underwent cMRIs and those who did not. The variable timing at which cMRIs were obtained may also make findings (or lack of) findings difficult to interpret. We only studied the acute course of patients and do not have appreciable follow-up information. Patients in this series were evaluated at academic medical centers and may have been more seriously ill than patients in the community.

In conclusion, our case series demonstrates that myocarditis temporally related to COVID-19 vaccination is characterized by a mild illness with rapid resolution of symptoms in most patients. However, longer-term outcome data are lacking. We emphasize the importance of reporting suspected myocarditis cases after COVID-19 vaccination to the US Vaccine Adverse Events Reporting System or similar reporting systems for patients in other countries to better define the characteristics of this syndrome and its relationship to the receipt of COVID-19 vaccines. Future studies that focus on determining risk factors and mechanisms of develop-

ment of myocarditis are urgently needed, in particular, as COVID-19 vaccines become more widely available to younger children in the future.

ARTICLE INFORMATION

Received July 14, 2021; accepted November 2, 2021.

Affiliations

Division of Pediatric Cardiology, University of Utah and Primary Children's Hospital, Salt Lake City (D.T.T., L.M.L.). Department of Cardiology, Boston Children's Hospital, Department of Pediatrics; Harvard Medical School, MA (A.D., J.W.N.). Nicklaus Children's Hospital, Miami, FL (J.C.M.). Department of Pediatrics, Medical University of South Carolina, Charleston (K.E.M., A.M.A.). Seattle Children's, Department of Pediatrics, University of Washington (M.A.P., J.S.). Nemours Cardiac Center, Nemours Children's Health, Wilmington, DE (D.T., S.S.). Division of Cardiology, The Children's Hospital of Philadelphia, PA (M.D.E., T.M.G.). Duke University School of Medicine, Durham, NC (J.S.L., M.J.C.). Connecticut Children's Medical Center and University of Connecticut School of Medicine, Farmington (O.H.T.-S.). Division of Pediatric Cardiology; NewYork-Presbyterian/Columbia University Irving Medical Center (B.R.A.). Oregon Health & Science University, Division of Pediatric Cardiology, Department of Pediatrics, Portland (C.M.B., C.R.). The Heart Institute, Joe DiMaggio Children's Hospital, Hollywood, FL (M.C., L.D.A.). Division of Pediatric Cardiology, Department of Pediatrics, University of California San Diego and Rady Children's Hospital San Diego (K.B.D.). Division of Pediatric Cardiology, Children's Mercy, Kansas City, MO (D.F.). Division of Cardiology, Children's National Hospital, Washington, DC (L.H.F., A.K.). Division of Pediatric Cardiology, C.S. Mott Children's Hospital, University of Michigan, Ann Arbor (O.H.F., S.K.G.). Children's of Alabama Department of Pediatrics, Division of Pediatric Cardiology, University of Alabama at Birmingham School of Medicine (C.H.). Maria Fareri Children's Hospital at Westchester Medical Center/ New York Medical College, Valhalla (S.S.J.). University of North Carolina at Chapel Hill (P.J., J.R.S.). Warren Alpert Medical School of Brown University; Division of Pediatric Cardiology, Hasbro Children's Hospital, Providence, RI (K.C.L.). Department of Paediatrics, The Hospital for Sick Children, University of Toronto, Canada (B.W.M., T.M.). Cohen Children's Medical Center (Northwell Health), New Hyde Park, NY (E.C.M.). Kawasaki Disease Research Center, Department of Pediatrics, University of California San Diego, La Jolla and Rady Children's Hospital San Diego (K.M.). Division of Critical Care, Connecticut Children's, Hartford (R.M.P.). Division of Pediatric Cardiology, Riley Children's Hospital, Indianapolis, IN (J.K.P.). Division of Pediatric Cardiology, Phoenix Children's Hospital, AZ (A.A.S.). Baylor College of Medicine, Texas Children's Hospital, Houston, TX (S.K.S.T., L.S.S.). Division of Cardiology (J.K.V.-S.), Division of Hospital Medicine (S.W.), Children's Hospital Los Angeles and Keck School of USC, CA.

Sources of Funding

Dr Newburger was funded in part by the McCance Foundation and the Kostin Family Innovation Fund.

Disclosures

Dr Anderson has received research grants from the National Institutes of Health, Genentech for COVID-related research. Drs Newburger and Truong are consultants for Pfizer for vaccine-associated myocarditis (pending). The other authors have no disclosures to report.

Supplemental Material

Tables S1 and S2

REFERENCES

1. Ammirati E, Cavalotti C, Milazzo A, Pedrotti P, Soriano F, Schroeder JW, Morici N, Giannattasio C, Frigerio M, Metra M, et al. Temporal relation between second dose BNT162b2 mRNA Covid-19 vaccine and cardiac involvement in a patient with previous SARS-COV-2 infection. *Int J Cardiol Heart Vasc*. 2021;100778. doi: 10.1016/j.ijch.2021.100774
2. Larson KF, Ammirati E, Adler ED, Cooper LT Jr, Hong KN, Saponara G, Couri D, Cereda A, Procopio A, Cavalotti C, et al. Myocarditis after BNT162b2 and mRNA-1273 vaccination. *Circulation*. 2021;144:506–508. doi: 10.1161/CIRCULATIONAHA.121.055913
3. Li X, Ostropelets A, Makadia R, Shoabi A, Rao G, Sena AG, Martinez-Hernandez E, Delmestri A, Verhamme K, Rijnbeek PR, et al. Characterising the background incidence rates of adverse events of special interest for covid-19 vaccines in eight countries: multinational network cohort study. *BMJ*. 2021;373:n1435.
4. Mevorach D, Anis E, Cedar N, Bromberg M, Haas EJ, Nadir E, Olsha-Castell S, Arad D, Hasin T, Levi N, et al. Myocarditis after BNT162b2 mRNA vaccine against Covid-19 in Israel. *N Engl J Med*. 2021;385:2140–2149. doi: 10.1056/NEJMoa2109730.
5. Montgomery J, Ryan M, Engler R, Hoffman D, McClenathan B, Collins L, Loran D, Hrcir D, Herringer K, Platzer M, et al. Myocarditis following immunization with mRNA COVID-19 vaccines in members of the US military. *JAMA Cardiol*. 2021;6:1202–1206. doi: 10.1001/jamacardio.2021.2833
6. McLean K, Johnson TJ. Myopericarditis in a previously healthy adolescent male following COVID-19 vaccination: a case report. *Acad Emerg Med*. 2021;28:918–921. doi: 10.1111/acem.14322
7. Abu Mouch S, Roguin A, Hellou E, Ishai A, Shoshan U, Mahamid L, Zoabi M, Aisman M, Goldschmid N, Berar Yanay N. Myocarditis following COVID-19 mRNA vaccination. *Vaccine*. 2021;39:3790–3793. doi: 10.1016/j.vaccine.2021.05.087
8. Marshall M, Ferguson ID, Lewis P, Jaggi P, Gagliardo C, Collins JS, Shaughnessy R, Caron R, Fuss C, Corbin KJE, et al. Symptomatic acute myocarditis in 7 adolescents after Pfizer-BioNTech COVID-19 vaccination. *Pediatrics*. 2021;148:e2021052478. doi: 10.1542/peds.2021-052478
9. Halseil JS, Riddle JR, Atwood JE, Gardner P, Shope R, Poland GA, Gray GC, Ostroff S, Eckart RE, Hospenthal DR, et al. Department of Defense Smallpox Vaccination Clinical Evaluation Team. Myopericarditis following smallpox vaccination among vaccinia-naive US military personnel. *JAMA*. 2003;289:3283–3289. doi: 10.1001/jama.289.24.3283
10. Kim YJ, Bae JI, Ryou SM, Kim WY. Acute fulminant myocarditis following influenza vaccination requiring extracorporeal membrane oxygenation. *Acute Crit Care*. 2019;34:165–169. doi: 10.4266/acc.2017.00045
11. Gargano JW, Wallace M, Hadler SC, Langley G, Su JR, Oster ME, Broder KR, Gee J, Weintraub E, Shimabukuro T, et al. Use of mRNA COVID-19 vaccine after reports of myocarditis among vaccine recipients: update from the Advisory Committee on Immunization Practices – United States, June 2021. *MMWR Morb Mortal Wkly Rep*. 2021;70:977–982. doi: 10.15585/mmwr.mm7027e2
12. Caforio AL, Pankuweit S, Arbustini E, Basso C, Gimeno-Blanes J, Felix SB, Fu M, Heliö T, Heymans S, Jahns R, et al; European Society of Cardiology Working Group on Myocardial and Pericardial Diseases. Current state of knowledge on aetiology, diagnosis, management, and therapy of myocarditis: a position statement of the European Society of Cardiology Working Group on Myocardial and Pericardial Diseases. *Eur Heart J*. 2013;34:2636–48, 2648a. doi: 10.1093/eurheartj/ehd210
13. Bozkurt B, Colvin M, Cook J, Cooper LT, Deswal A, Fonarow GC, Francis GS, Lenihan D, Lewis EF, McNamara DM, et al; American Heart Association Committee on Heart Failure and Transplantation of the Council on Clinical Cardiology; Council on Cardiovascular Disease in the Young; Council on Cardiovascular and Stroke Nursing; Council on Epidemiology and Prevention; and Council on Quality of Care and Outcomes Research. Current diagnostic and treatment strategies for specific dilated cardiomyopathies: a scientific statement from the American Heart Association. *Circulation*. 2016;134:e579–e646. doi: 10.1161/CIR.0000000000000455
14. Ferreira VM, Schulz-Menger J, Holmvang G, Kramer CM, Carbone I, Sechtem U, Kindermann I, Gutberlet M, Cooper LT, Liu P, et al. Cardiovascular magnetic resonance in nonischemic myocardial inflammation: expert recommendations. *J Am Coll Cardiol*. 2018;72:3158–3176. doi: 10.1016/j.jacc.2018.09.072
15. Centers for Disease Control and Prevention. CDC Health Advisory: multi-system inflammatory syndrome in children (MIS-C) associated with coronavirus disease 2019 (COVID-19). Published May 14, 2020. Accessed July 4, 2021. <https://emergency.cdc.gov/han/2020/han00432.asp>
16. McCrindle BW, Rowley AH, Newburger JW, Burns JC, Bolger AF, Gewitz M, Baker AL, Jackson MA, Takahashi M, Shah PB, et al; American Heart Association Rheumatic Fever, Endocarditis, and Kawasaki Disease Committee of the Council on Cardiovascular Disease in the Young; Council on Cardiovascular and Stroke Nursing; Council on Cardiovascular Surgery and Anesthesia; and Council on Epidemiology and Prevention. Diagnosis, treatment, and long-term management of Kawasaki disease: a scientific statement for health professionals from the American Heart Association. *Circulation*. 2017;135:e927–e999. doi: 10.1161/CIR.0000000000000484
17. Caforio ALP, Malipiero G, Marcolongo R, Iliceto S. Clinically suspected myocarditis with pseudo-infarct presentation: the role of endomyocardial biopsy. *J Thorac Dis*. 2017;9:423–427. doi: 10.21037/jtd.2017.03.103

18. Fan Y, Chen M, Liu M, Yang X. Myocarditis with chest pain, normal heart function and extreme increased troponin. *Int J Cardiol.* 2016;209:307–309. doi: 10.1016/j.ijcard.2016.01.037
19. Rosner CM, Genovese L, Tehrani BN, Atkins M, Bakhshi H, Chaudhri S, Damluji AA, de Lemos JA, Desai SS, Emamina A, et al. Myocarditis temporally associated with COVID-19 vaccination. *Circulation.* 2021;144:502–505. doi: 10.1161/CIRCULATIONAHA.121.055891
20. Schauer J, Buddha S, Colyer J, Sagiv E, Law Y, Mallenahalli Chikkabyrappa S, Portman MA. Myopericarditis after the Pfizer messenger ribonucleic acid coronavirus disease vaccine in adolescents. *J Pediatr.* 2021;238:317–320. doi: 10.1016/j.jpeds.2021.06.083
21. Jain SS, Steele JM, Fonseca B, Huang S, Shah S, Maskatia SA, Buddha S, Misra N, Ramachandran P, Gaur L, et al. COVID-19 vaccination-associated myocarditis in adolescents. *Pediatrics.* 2021;148:e2021053427. doi: 10.1542/peds.2021-053427
22. Wallace M, Oliver S. COVID-19 mRNA vaccines in adolescents and young adults: benefit-risk discussion. Centers for Disease Control and Prevention. Published June 5, 2021. Accessed June 30, 2021. <https://www.cdc.gov/vaccines/acip/meetings/downloads/slides-2021-06/05-COVID-Wallace-508.pdf>
23. Rached-D'Astous S, Boukas I, Fournier A, Raboisson MJ, Dahdah N. Coronary artery dilatation in viral myocarditis mimics coronary artery findings in Kawasaki disease. *Pediatr Cardiol.* 2016;37:1148–1152. doi: 10.1007/s00246-016-1411-x
24. Ciuca C, Fabi M, Di Luca D, Niro F, Ghizzi C, Donti A, Balducci A, Rocca A, Zarbo C, Gargiulo GD, et al. Myocarditis and coronary aneurysms in a child with acute respiratory syndrome coronavirus 2. *ESC Heart Fail.* 2021;8:761–765. doi: 10.1002/ehf2.13048
25. de Zorzi A, Colan SD, Gauvreau K, Baker AL, Sundel RP, Newburger JW. Coronary artery dimensions may be misclassified as normal in Kawasaki disease. *J Pediatr.* 1998;133:254–258. doi: 10.1016/s0022-3476(98)70229-x
26. Centers for Disease Control and Prevention. COVID Data Tracker. Demographic trends of COVID-19 cases and deaths in the US reported to CDC. Accessed July 4, 2021. <https://covid.cdc.gov/covid-data-tracker/#demographics>
27. Vasudeva R, Bhatt P, Lilje C, Desai P, Amponsah J, Umscheid J, Parmar N, Bhatt N, Adupa R, Pagad S, et al. Trends in acute myocarditis related pediatric hospitalizations in the United States, 2007–2016. *Am J Cardiol.* 2021;149:95–102. doi: 10.1016/j.amjcard.2021.03.019
28. Fairweather D, Cooper LT Jr, Blauwet LA. Sex and gender differences in myocarditis and dilated cardiomyopathy. *Curr Probl Cardiol.* 2013;38:7–46. doi: 10.1016/j.cpcardiol.2012.07.003
29. Kytö V, Sipilä J, Rautava P. The effects of gender and age on occurrence of clinically suspected myocarditis in adulthood. *Heart.* 2013;99:1681–1684. doi: 10.1136/heartjnl-2013-304449
30. Pesce M, Agostoni P, Bøtker HE, Brundel B, Davidson SM, Caterina R, Ferdinandy P, Girao H, Gyöngyösi M, Hulot JS, et al. COVID-19-related cardiac complications from clinical evidences to basic mechanisms: opinion paper of the ESC Working Group on Cellular Biology of the Heart. *Cardiovasc Res.* 2021;117:2148–2160. doi: 10.1093/cvr/cvab201
31. Consiglio CR, Cotugno N, Sardi F, Pou C, Amodio D, Rodriguez L, Tan Z, Zicari S, Ruggiero A, Pascucci GR, et al; CACTUS Study Team. The immunology of multisystem inflammatory syndrome in children with COVID-19. *Cell.* 2020;183:968–981.e7. doi: 10.1016/j.cell.2020.09.016
32. Gruber CN, Patel RS, Trachtman R, Lepow L, Amanat F, Krammer F, Wilson KM, Onel K, Geanon D, Tuballes K, et al. Mapping systemic inflammation and antibody responses in multisystem inflammatory syndrome in children (MIS-C). *Cell.* 2020;183:982–995.e14. doi: 10.1016/j.cell.2020.09.034
33. Galeotti C, Bayry J. Autoimmune and inflammatory diseases following COVID-19. *Nat Rev Rheumatol.* 2020;16:413–414. doi: 10.1038/s41584-020-0448-7
34. Bozkurt B, Kamat I, Hotez PJ. Myocarditis with COVID-19 mRNA vaccines. *Circulation.* 2021;144:471–484. doi: 10.1161/CIRCULATIONAHA.121.056135
35. Negron SG, Kessinger CW, Xu B, Pu WT, Lin Z. Selectively expressing SARS-CoV-2 Spike protein S1 subunit in cardiomyocytes induces cardiac hypertrophy in mice. *bioRxiv*. Preprint posted online June 20, 2021. doi: 10.1101/2021.06.20.448993
36. Chen HS, Wang W, Wu SN, Liu JP. Corticosteroids for viral myocarditis. *Cochrane Database Syst Rev.* 2013;CD004471.
37. Canter CE, Simpson KE, Simpson KP. Diagnosis and treatment of myocarditis in children in the current era. *Circulation.* 2014;129:115–128. doi: 10.1161/CIRCULATIONAHA.113.001372
38. McArdle AJ, Vito O, Patel H, Seaby EG, Shah P, Wilson C, Broderick C, Nijman R, Tremoulet AH, Munblit D, et al; BATS Consortium. Treatment of multisystem inflammatory syndrome in children. *N Engl J Med.* 2021;385:11–22. doi: 10.1056/NEJMoa2102968
39. Belhadjer Z, Auriou J, Méot M, Oualha M, Renolleau S, Houyel L, Bonnet D. Addition of corticosteroids to immunoglobulins is associated with recovery of cardiac function in multi-inflammatory syndrome in children. *Circulation.* 2020;142:2282–2284. doi: 10.1161/CIRCULATIONAHA.120.050147
40. Ouldali N, Toubiana J, Antona D, Javouhey E, Madhi F, Lorrot M, Léger PL, Galeotti C, Claude C, Wiedemann A, et al; French Covid-19 Paediatric Inflammation Consortium. Association of intravenous immunoglobulins plus methylprednisolone vs immunoglobulins alone with course of fever in multi-system inflammatory syndrome in children. *JAMA.* 2021;325:855–864. doi: 10.1001/jama.2021.0694
41. Berg J, Lovrinovic M, Baltensperger N, Kissel CK, Kottwitz J, Manka R, Patriki D, Scherff F, Schmied C, Landmesser U, et al. Non-steroidal anti-inflammatory drug use in acute myopericarditis: 12-month clinical follow-up. *Open Heart.* 2019;6:e000990. doi: 10.1136/openhrt-2018-000990
42. Meune C, Spaulding C, Mahé I, Lebon P, Bergmann JF. Risks versus benefits of NSAIDs including aspirin in myocarditis: a review of the evidence from animal studies. *Drug Saf.* 2003;26:975–981. doi: 10.2165/0002018-200326130-00005
43. Imazio M, Brucato A, Cemin R, Ferrua S, Maggolini S, Beqaraj F, Demarie D, Forno D, Ferro S, Maestroni S, et al; ICAP Investigators. A randomized trial of colchicine for acute pericarditis. *N Engl J Med.* 2013;369:1522–1528. doi: 10.1056/NEJMoa1208536
44. Feldstein LR, Tenforde MW, Friedman KG, Newhams M, Rose EB, Dapul H, Soma VL, Maddux AB, Mourani PM, Bowens C, et al; Overcoming COVID-19 Investigators. Characteristics and outcomes of US children and adolescents with multisystem inflammatory syndrome in children (MIS-C) compared with severe acute COVID-19. *JAMA.* 2021;325:1074–1087. doi: 10.1001/jama.2021.2091
45. Dufort EM, Koumans EH, Chow EJ, Rosenthal EM, Muse A, Rowlands J, Barranco MA, Maxted AM, Rosenberg ES, Easton D, et al; New York State and Centers for Disease Control and Prevention Multisystem Inflammatory Syndrome in Children Investigation Team. Multisystem inflammatory syndrome in children in New York State. *N Engl J Med.* 2020;383:347–358. doi: 10.1056/NEJMoa2021756
46. Valverde I, Singh Y, Sanchez-de-Toledo J, Theocharis P, Chikermane A, Di Filippo S, Kucińska B, Mannarino S, Tamariz-Martel A, Gutierrez-Larraya F, et al; AEPC COVID-19 Rapid Response Team*. Acute cardiovascular manifestations in 286 children with multisystem inflammatory syndrome associated with COVID-19 infection in Europe. *Circulation.* 2021;143:21–32. doi: 10.1161/CIRCULATIONAHA.120.050065
47. Baruch G, Rothschild E, Sadon S, Szekely Y, Lichter Y, Kaplan A, Taieb P, Banai A, Hochstadt A, Merdler I, et al. Evolution of right and left ventricle routine and speckle-tracking echocardiography in patients recovering from coronavirus disease 2019: a longitudinal study. *Eur Heart J Cardiovasc Imaging.* Published online September 20, 2021. doi: 10.1093/ehjci/jeab190
48. Matsubara D, Kauffman HL, Wang Y, Calderon-Anyosa R, Nadaraj S, Elias MD, White TJ, Torowicz DL, Yubbu P, Giglia TM, et al. Echocardiographic findings in pediatric multisystem inflammatory syndrome associated with COVID-19 in the United States. *J Am Coll Cardiol.* 2020;76:1947–1961. doi: 10.1016/j.jacc.2020.08.056
49. Law YM, Lal AK, Chen S, Čiháková D, Cooper LT Jr, Deshpande S, Godown J, Grosse-Wortmann L, Robinson JD, Towbin JA; American Heart Association Pediatric Heart Failure and Transplantation Committee of the Council on Lifelong Congenital Heart Disease and Heart Health in the Young and Stroke Council. Diagnosis and management of myocarditis in children: a scientific statement from the American Heart Association. *Circulation.* 2021;144:e123–e135. doi: 10.1161/CIR.0000000000001001
50. Shimabukuro T. COVID-19 vaccine safety updates: Vaccines and Related Biological Products Advisory Committee (VRBPAC). US Food and Drug Administration. Published June 10, 2021. Accessed July 4, 2021. <https://www.fda.gov/media/150054/download>